

## A giant pancreatic pseudocyst treated by open cystogastrostomy

ARTUR PASTERNAK<sup>1,2</sup>, PRZEMYSŁAW WAWOK<sup>1</sup>, PIOTR RICHTER<sup>1</sup>

<sup>1</sup>First Department of General, Oncological and Gastrointestinal Surgery  
Jagiellonian University Medical College, ul. Kopernika 40, 31-501 Kraków, Poland

<sup>2</sup>Department of Anatomy, Jagiellonian University Medical College  
ul. Kopernika 12, 31-034 Kraków, Poland

**Corresponding author:** Artur Pasternak; Department of Anatomy, Jagiellonian University Medical College  
ul. Kopernika 12, 31-034 Kraków, Poland  
Phone/Fax: +48 12 422 95 11; E-mail: artpast@tlen.pl

**Abstract:** We report a case of a giant pancreatic pseudocyst in a 33-year-old woman presenting with abdominal pain, loss of appetite and abdominal distension. CT scans revealed a giant pancreatic pseudocyst measuring 10.3 cm × 9.6 cm × 9.3 cm anteroposteriorly, with significant compression of the stomach. An open retrogastric cystogastrostomy was performed through a midline incision, and 3 L of fluid was drained from the pseudocyst. Recovery has been uneventful.

**Key words:** Giant Pancreatic Pseudocyst, Cystogastrostomy.

### Introduction

Pancreatic pseudocysts are the most common cystic lesions of the pancreas, associated with inflammatory and traumatic conditions of pancreas. Most of the pseudocysts usually resolve spontaneously and rarely produce complications. Pancreatic pseudocysts are defined as localized collections of pancreatic-enzyme-rich fluid and originating in or adjacent to the pancreas. Because these cavities are not lined with an epithelium, pseudocysts are not labeled as true cysts. We present a case of a large pseudocyst located in the tail of pancreas. Retrogastric cystogastrostomy (modified Jurasz procedure) was the procedure advocated for treatment.

## Case presentation

A 33-year-old female presented to our department with recurrent giant pancreatic pseudocyst after the episode of acute pancreatitis. She was admitted with history of abdominal pain, loss of appetite and abdominal distension. She had already undergone extracorporeal drainage twice before. Laboratory tests showed elevated level of amylase in the cystic fluid with normal levels of CA19-9 and carcinoembryonic antigen (CEA). Endoscopic retrograde cholangiopancreatography with sphincterotomy was also performed. An ultrasound examination and computed tomography (CT) scan revealed the presence of a cystic mass (10.3 cm × 9.6 cm × 9.3 cm) located in the pancreatic tail which compressed the gastric wall. Finally our patient was qualified for open surgery. Peritoneal access was established through midline incision. Operative findings showed a 20 × 20 cm cystic mass with a thick, grey white wall, tightly connected to the pancreatic tail and compressing stomach with dilation of gastrosplenic vessels (Fig. 1). Cystic wall was incised and 3 L of dark coloured fluid was drained. Debris were removed, cyst was cleaned with saline and part of its wall was excised for

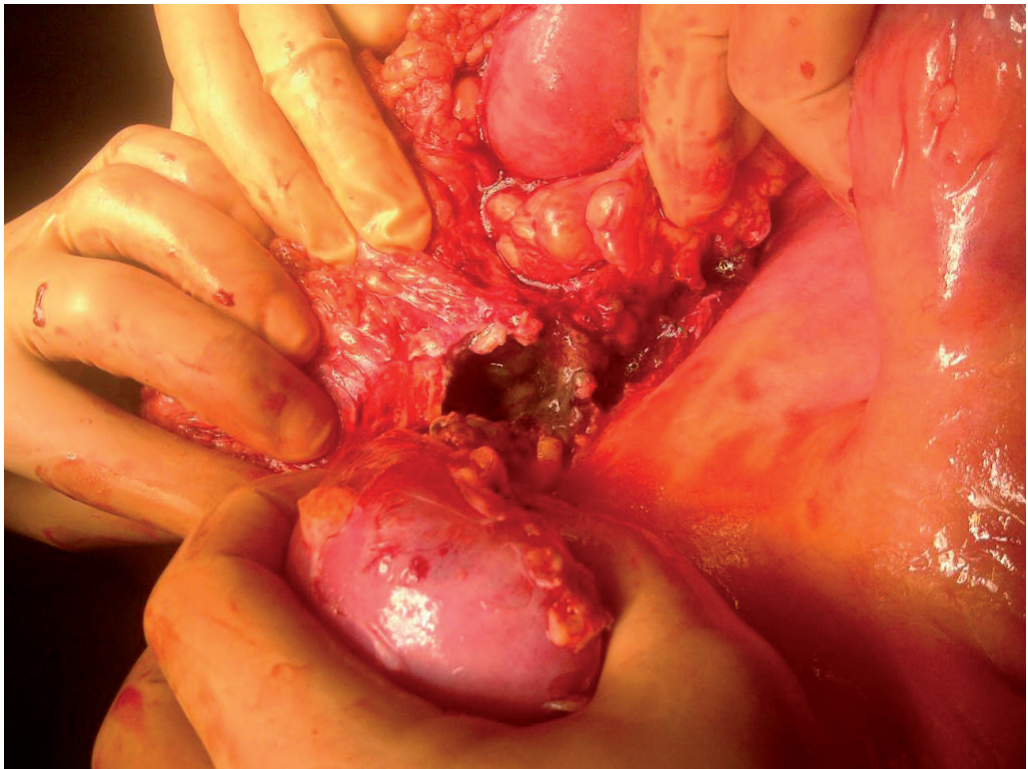


Fig. 1. Pancreatic pseudocyst — intraoperation view.

histopathology. Free posterior gastric wall along the greater curvature was mobilized and gastrotomy with subsequent anastomosis by vicryl suture in double layers to the incised cyst. The tube drain was placed in the peritoneal cavity. Postoperatively, the patient had an uneventful recovery and was discharged on the 7<sup>th</sup> postoperative day. Two months after discharge, follow-up evaluation with upper endoscopy and CT revealed complete resolution of the pseudocyst and no sign of recurrence. The patient was later routinely followed up with a repeat USG that showed no pseudocyst. Histological analysis of the specimen revealed nonepithelialized granulation tissue and fibrosis typical for pancreatic pseudocyst.

### Discussion

Differential diagnosis of pancreatic pseudocysts includes acute fluid collections, pancreatic abscesses, cystic pancreatic neoplasms, congenital or other pancreatic true cysts, parasitic cysts and extrapancreatic cysts. Mostly, pancreatic pseudocysts occur in the setting of previous pancreatic pathology such as inflammatory pancreatitis or posttraumatic ductal leakage. However, pancreatic pseudocysts can appear similar to radiographically to pancreatic cystic neoplasms such as cystadenomas and cystadenocarcinomas. In general, intracystic fluid from pseudocysts contains low levels of CEA, CA19-9, CA125, CA72-4 and viscosity but high pancreatic amylase and/or lipase activity.

The treatment of pancreatic pseudocysts today comprises invasive procedures i.e. percutaneous or endoscopic drainage and surgery. Decompression of the pseudocyst by percutaneous or internal drainage is advocated for symptomatic patients and the latter one can in turn be performed by endoscopic or surgical cystogastrostomy. Endoscopic cystogastrostomy is accomplished by the creation of a fistula and stent placement between the pseudocyst and the stomach and has technical and treatment success rates of 89%–100% and 82%–100%, respectively, and a mortality rate of less than 1% [1–6]. Surgical cystogastrostomy is the gold standard against other drainage procedures and involves creating an anastomosis between the pancreatic pseudocyst and the stomach and has technical and treatment success rates of greater than 90% and a mortality rate of 5%–10% [7–9]. It was first described in 1921 by Jedlicka and later (1931) modified by Jurasz [10, 11]. Until the early 1960s, transgastric or transventricular cystogastrostomy became a standard procedure in the treatment of mature pancreatic pseudocysts contacting the stomach. Antoni Tomasz Jurasz (1882–1961) described an approach to a pancreatic cyst through a transverse incision in the anterior gastric wall. A drainage opening between the cyst and the gastric lumen is created by incision in an area of the posterior gastric wall already adherent to the cyst through inflammation. Currently, the anastomosis is further secured by a continuous suture for hemostasis [12, 13]. In our case the position of the cyst was not satisfactory for transgastric approach and the

stomach was not involved in the inflammatory reaction so we decided to perform the retrogastric or external cystogastrostomy. It involves mobilization of the free posterior gastric wall along the greater curvature and gastrotomy with subsequent anastomosis by suture to the incised cyst. During the last decade, the conventional open approach for drainage of pancreatic pseudocysts has given way to laparoscopy — assisted pseudocystogastrostomy, a minimally invasive procedure with standardized stapler-performed anastomosis. In our department we prefer open vs. laparoscopic approach due to our own surgical experience, lower costs associated with quicker surgical time for the open approach, and elimination of the costs for laparoscopic equipment. Although laparoscopy is considered less invasive than open surgery, this technique is not widely used and, furthermore, there is no data about randomized trials that have directly compared the outcomes of both procedures.

## References

1. Bergman S., Melvin W.S.: Operative and nonoperative management of pancreatic pseudocysts. *Surg Clin North Am.* 2007; 87: 1447–1460.
2. Binmoeller K.F., Seifert H., Walter A., et al.: Transpapillary and transmural drainage of pancreatic pseudocysts. *Gastrointest Endosc.* 1995; 42: 219–224.
3. Ahn J.Y., Seo D.W., Eum J., et al.: Single-step EUS-guided transmural drainage of pancreatic pseudocysts: analysis of technical feasibility, efficacy, and safety. *Gut Liver.* 2010; 4: 524–529.
4. Kahaleh M., Shami V.M., Conaway M.R., et al.: Endoscopic ultrasound drainage of pancreatic pseudocyst: a prospective comparison with conventional endoscopic drainage. *Endoscopy.* 2006; 38: 355–359.
5. Antillon M.R., Shah R.J., Stiegmann G., et al.: Single-step EUS-guided transmural drainage of simple and complicated pancreatic pseudocysts. *Gastrointest Endosc.* 2006; 63: 797–803.
6. Azar R.R., Oh Y.S., Janee E.M., et al.: Wire-guided pancreatic pseudocyst drainage by using a modified needle knife and therapeutic echoendoscope. *Gastrointest Endosc.* 2006; 63: 688–692.
7. Parks R.W., Tzovaras G., Diamond T., et al.: Management of pancreatic pseudocysts. *Ann R Coll Surg Engl.* 2000; 82: 383–387.
8. Melman L., Azar R., Beddow K., et al.: Primary and overall success rates for clinical outcomes after laparoscopic, endoscopic, and open pancreatic cystogastrostomy for pancreatic pseudocysts. *Surg Endosc.* 2009; 23: 267–271.
9. Johnson M.D., Walsh R.M., Henderson J.M., et al.: Surgical versus nonsurgical management of pancreatic pseudocysts. *J Clin Gastroenterol.* 2009; 43: 586–590.
10. Magowska A.: A doctor facing turbulent times: Antoni Tomasz Jurasz, citizen of the world. *World J Surg.* 2011; 35 (9): 2167–2171.
11. Varadarajulu S., Bang J.Y., Sutton B.S., et al.: Equal Efficacy of Endoscopic and Surgical Cystogastrostomy for Pancreatic Pseudocyst Drainage in a Randomized Trial *Gastroenterology.* 2013; 145 (3): 583–590.
12. Karavias T., Dollinger P., Häring R.: Cystogastrostomy in the Treatment of Pancreatic Pseudocysts. In: *Standards in Pancreatic Surgery.* Eds. H.G. Beger, M. Büchler, P. Malferteiner. Berlin, Heidelberg: Springer 1993; 540–543.
13. Wang G.C., Misra S.: A giant pancreatic pseudocyst treated by cystogastrostomy. *BMJ Case Rep pii.* 2015. bcr2014207271. doi: 10.1136/bcr-2014-207271.